

Optometry Times

eBOOK

# FIVE THINGS YOU'RE MISSING WITH YOUR FUNDUS CAMERA

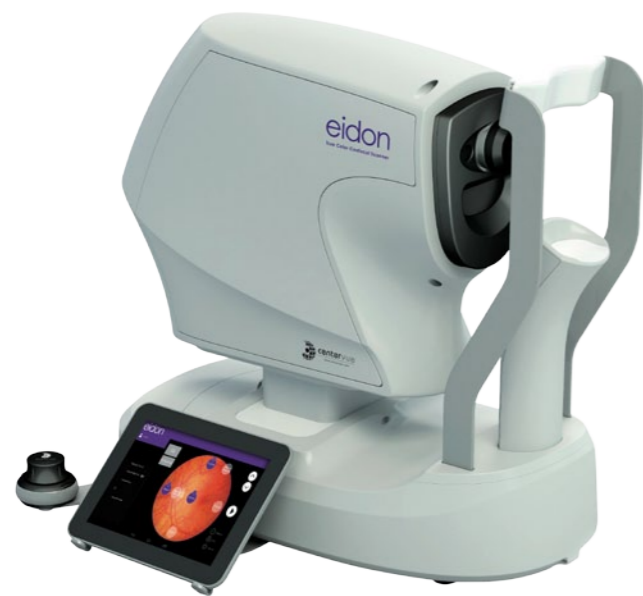*By Donald J. Siegel, OD, Sun City West Eye Care*

Sponsored by:



centervue

Optometry Times



Before I began incorporating EIDON true-color imaging into my practice, my retinal exams involved viewing one small section of retina at a time with a 90D and 20D lens and then mentally trying to put it all together into a comprehensive assessment of the full retina. What the EIDON has allowed me to do is have a wide-field, high-resolution retinal image projected across a large monitor to direct my exam. While it may image the fundus, this device is so much more than a fundus camera. Here are my top 5 aspects of retinal imaging with the EIDON wide-field true-color scanner that a traditional fundus camera cannot provide.

— Donald J. Siegel, OD, Sun City West Eye Care

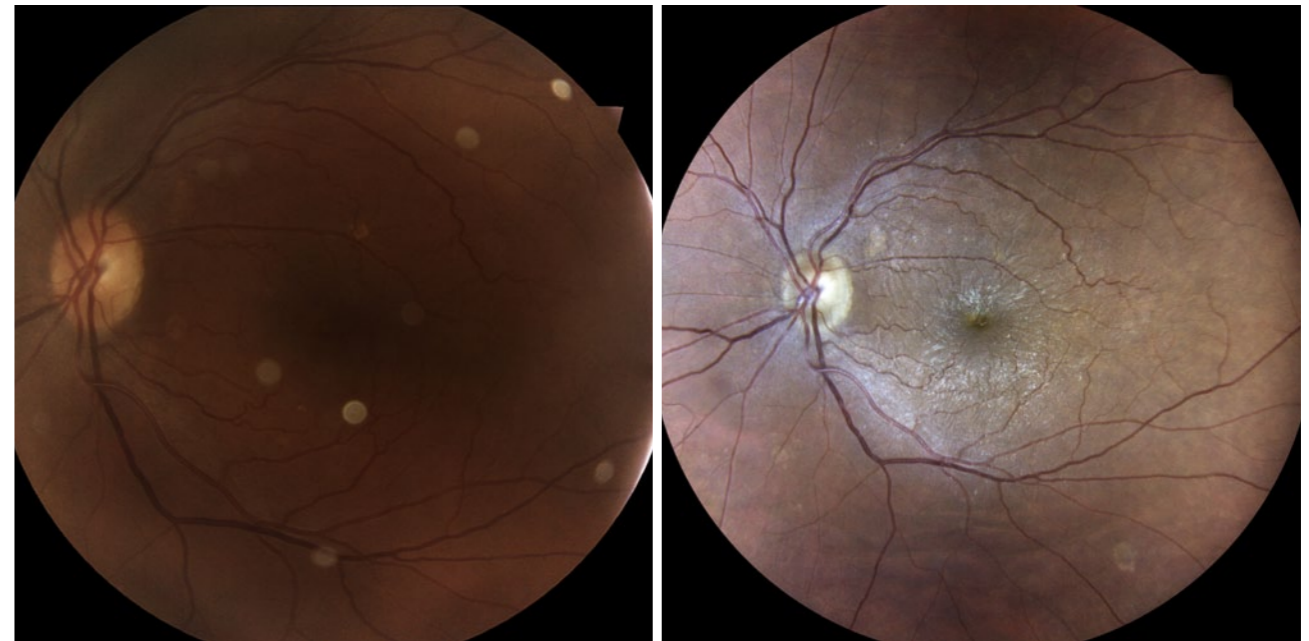
# 1

## Superior color, contrast and detail

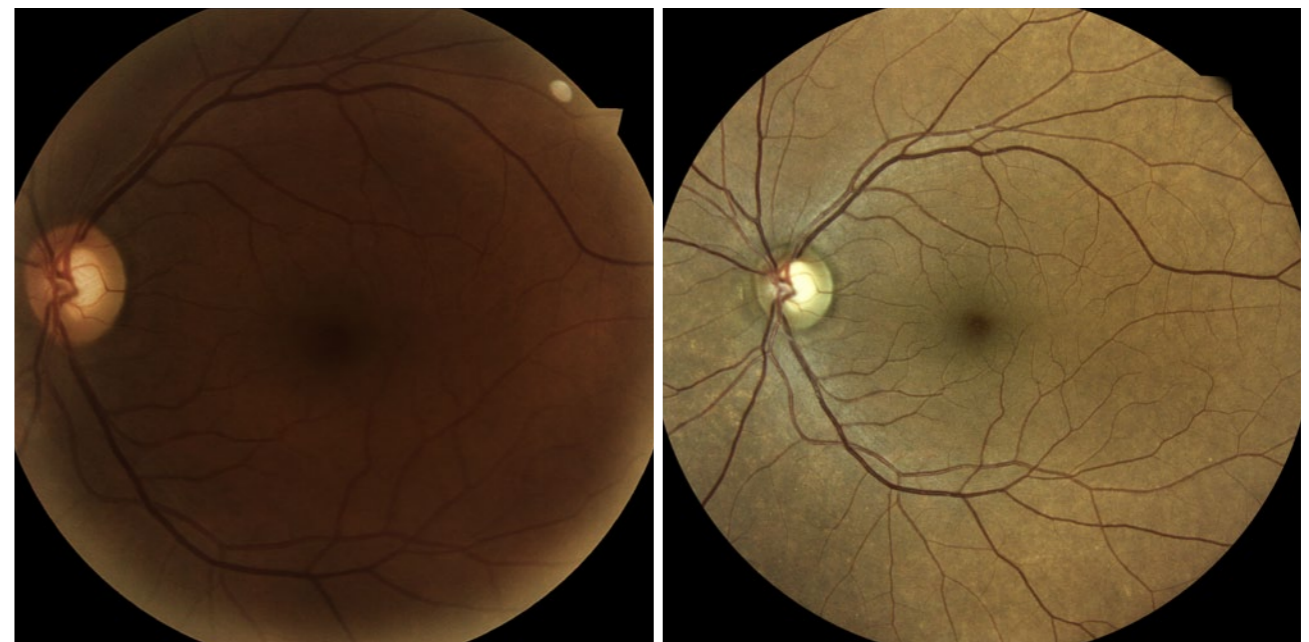The superior clarity of EIDON confocal imaging allows us to do a better job of detecting change in our patients. The resolution is so much higher than with a fundus camera that I can zoom the image and look at the vessels in extreme detail. These images readily show the tiniest microaneurysms and dot hemorrhages. The EIDON allows me to accurately document the extent and location of these hemorrhages which is incredibly helpful to monitor our patients for change on follow-up.

The EIDON offers true-color imaging with little loss of resolution, even at heightened zoom. Its infrared confocal scan of the deep retinal layers better defines the borders of a pathology that disrupts the retinal pigment epithelial layer showing the true extent of a

CLICK EACH IMAGE TO ENLARGE



Epiretinal Membrane with a standard fundus camera and with a 60° EIDON Image



Glaucoma and Cataract with a standard fundus camera and with a 60° EIDON Image

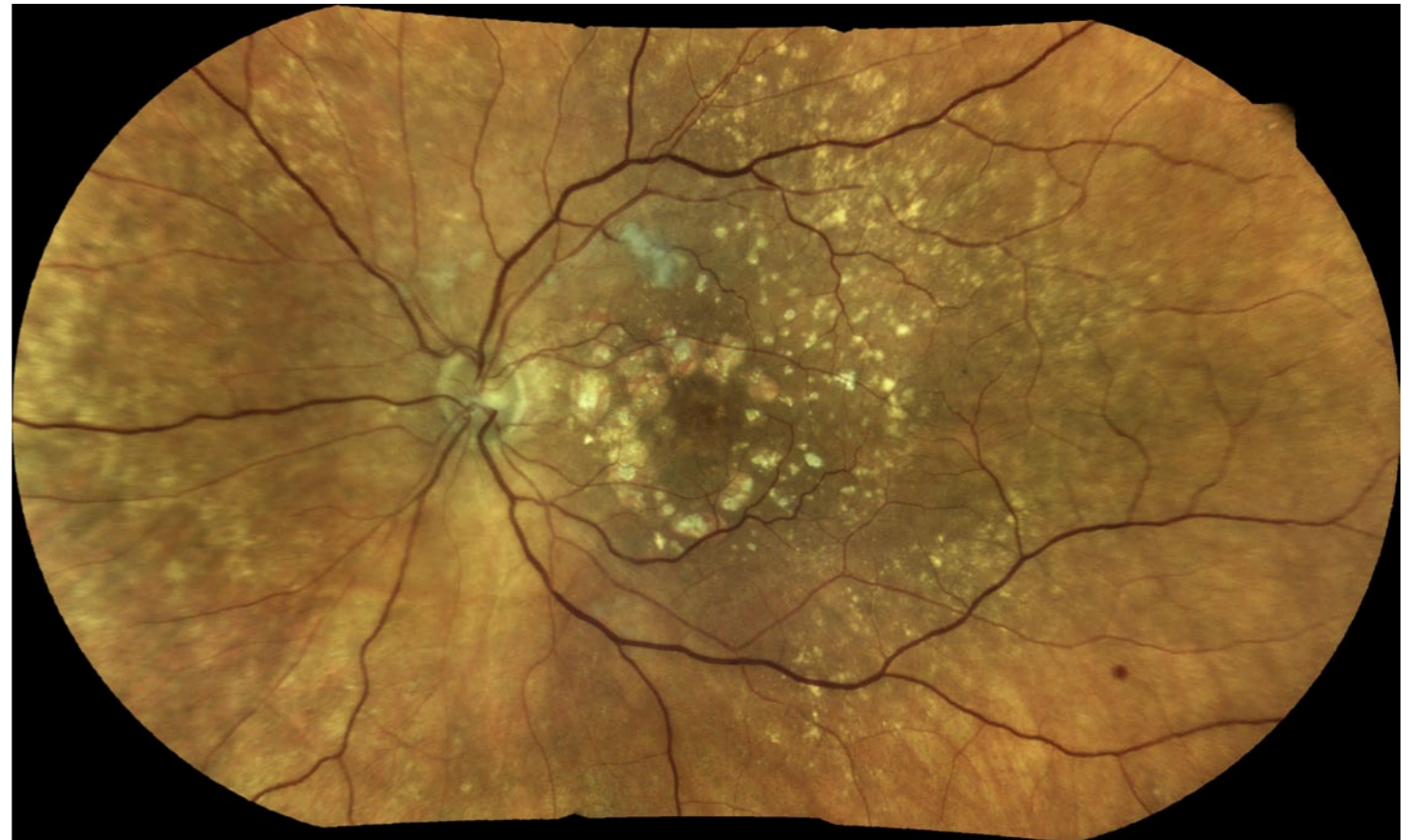1

*Continued*

nevus or AMD. That, in turn, allows for more accurate monitoring than other technologies. Fundus cameras do not view the deep layers of the retina; they only see the surface.

Finally, there's the ease of use. The operation of EIDON is so simple that there's no quality difference in the images captured by different staff members using this instrument, where that would not be true with a fundus camera.

CLICK EACH IMAGE TO ENLARGE



EIDON wide-field mosaic of Hypertensive Retinopathy and AMD

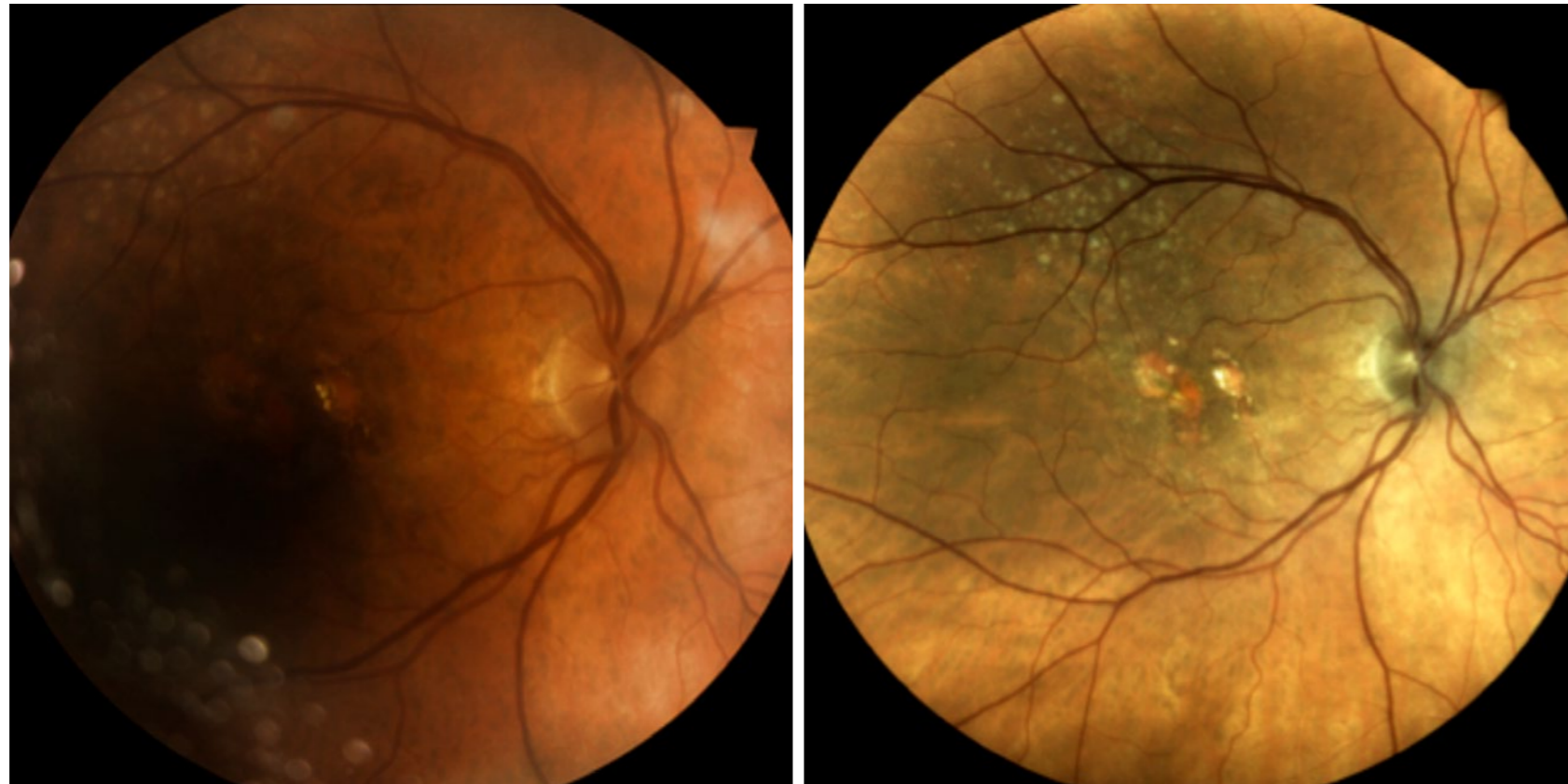
# 2

## Imaging through cataracts, media opacities and small pupils

EIDON's unique confocal view of the retina combined with white light illumination allows it to image through a dense cataract. Fundus cameras cannot clearly image through significant cataracts, and are equally unable to provide a good image if the eye has

capsular haze on an intraocular lens. In addition to imaging through media opacities, imaging through a poorly dilated or non-dilated pupil is something EIDON does extremely well where a standard fundus camera cannot image at all when the pupil is small.

CLICK EACH IMAGE TO ENLARGE



Standard fundus camera on the left and EIDON image on the right taken on an 85 year old patient without pupil dilation

This ability to image the retina through small apertures such as a dense capsular opacity that has undergone Nd:YAG laser is crucial for managing older patients.

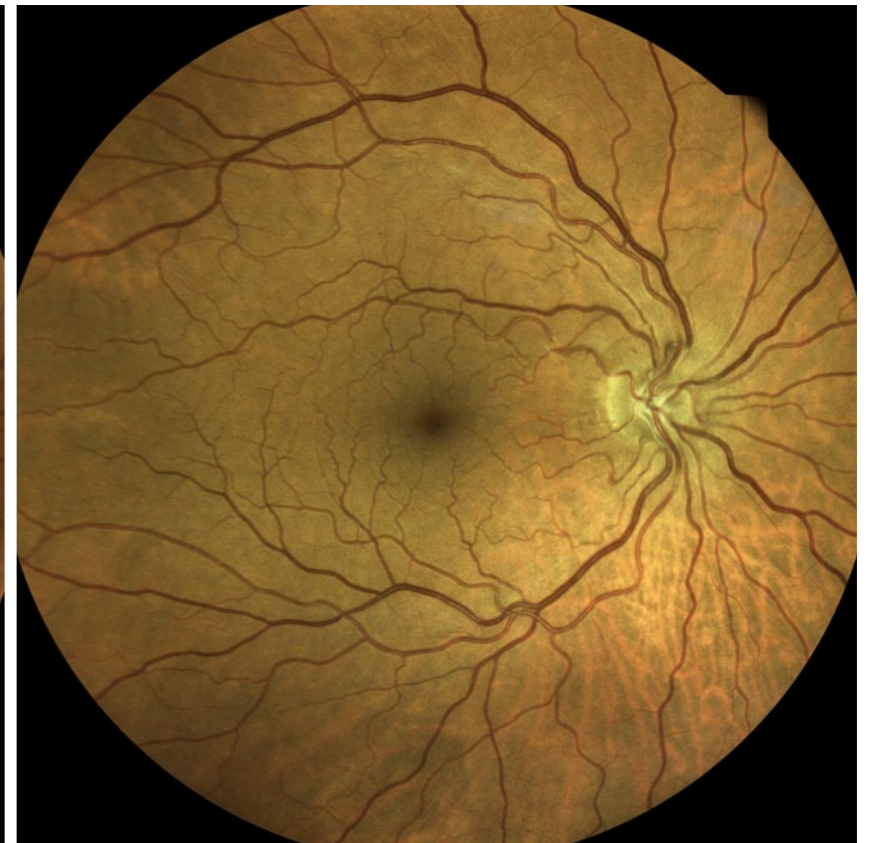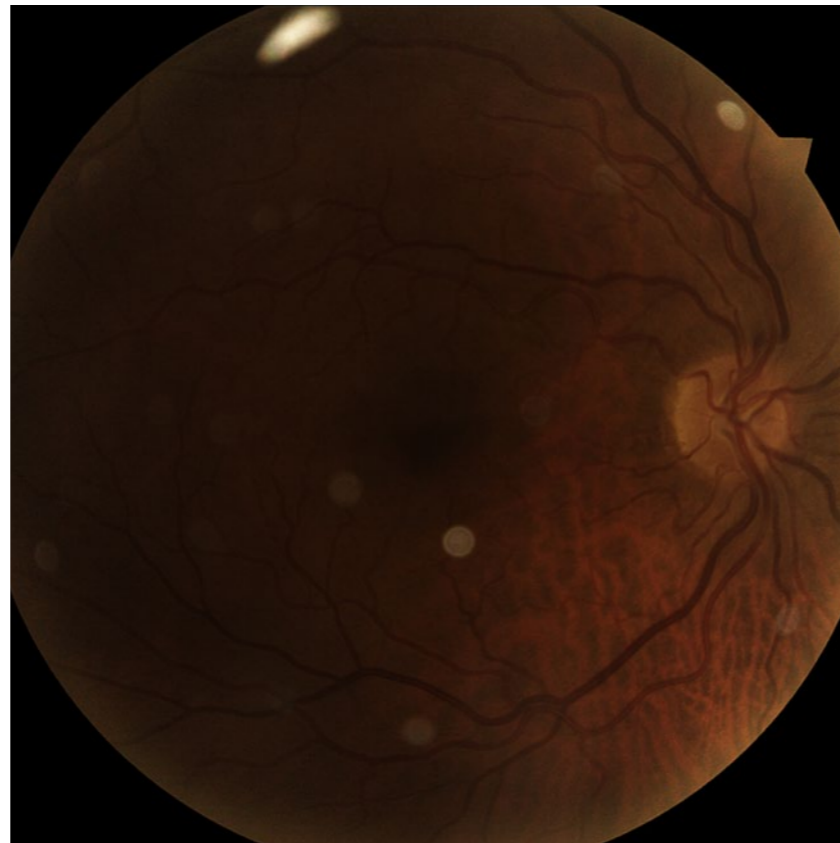
Similarly, an older patient may present with poor vision or out of date glasses where we would like to dilate on that

2

*Continued*

visit but doing so would make them unsafe to drive. In these patients an undilated 90D lens slit-lamp exam may see little or no retinal structures. When it is unsafe to dilate a patient with limited vision and no driver, we can still almost always get a central 60 degree fundus image using our EIDON to observe the most important retinal anatomy. We can then reschedule the dilated exam.

CLICK EACH IMAGE TO ENLARGE



Cataract with a standard fundus camera and a 60° EIDON image

# 3

## Earlier detection of pathology

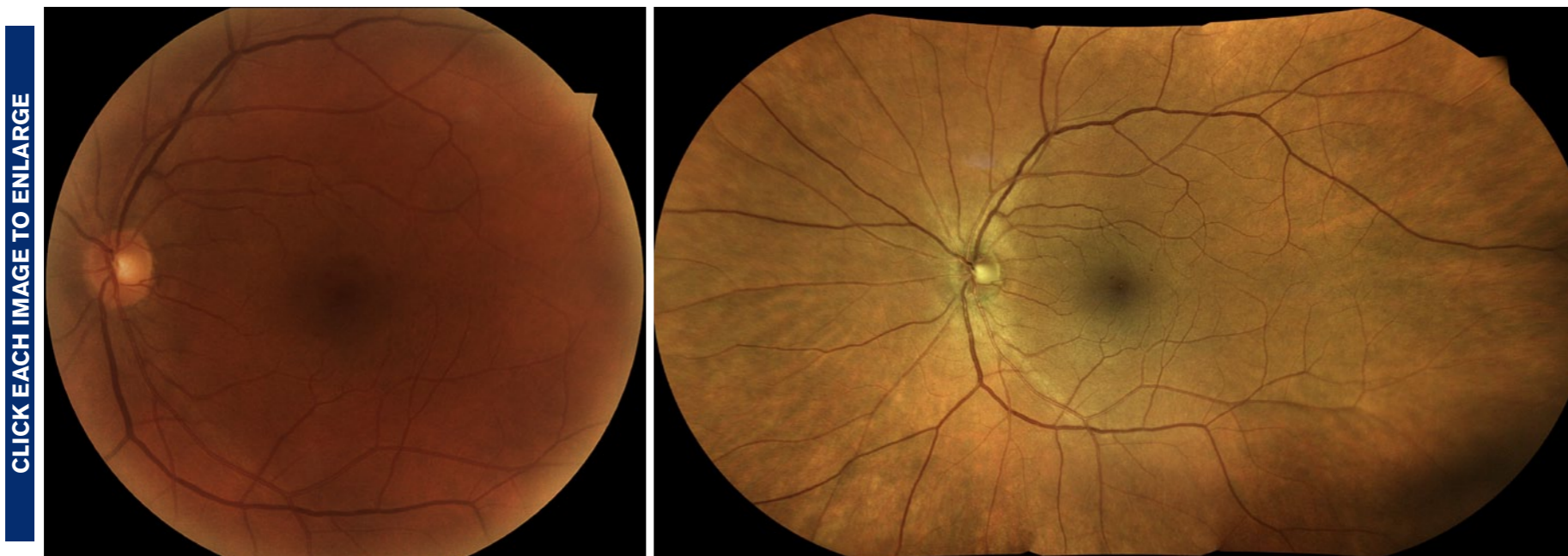The reason we take images of the fundus is to look for pathology and document ongoing disease, and today's fundus cameras are technically inferior to the EIDON.

EIDON will reveal tiny, dot hemorrhages or early macular drusen that I would not be able to see with a standard fundus camera. If the patient's eyes are watering, or they are squinting or unsteady during the slit lamp fundus examination, these small signs of ocular disease may be missed entirely on a direct

examination so the detailed EIDON images may be the only way you would detect these changes.

It's easy to tell a diabetic patient that without good control of their diabetes, permanent loss of vision is a possibility, as are problems with the cardiovascular system, feet and kidneys. But it's another to be able to show that same patient that in the year since they last saw us, they've developed retinal hemorrhages and their lack of tight diabetic control is causing real

and visible damage. Some of our diabetic patients do not realize the severity of the disease. Once we image the retina and can show them that they've started hemorrhaging,



Subtle Diabetic Retinopathy with a standard fundus camera and EIDON wide-field mosaic

3

*Continued*

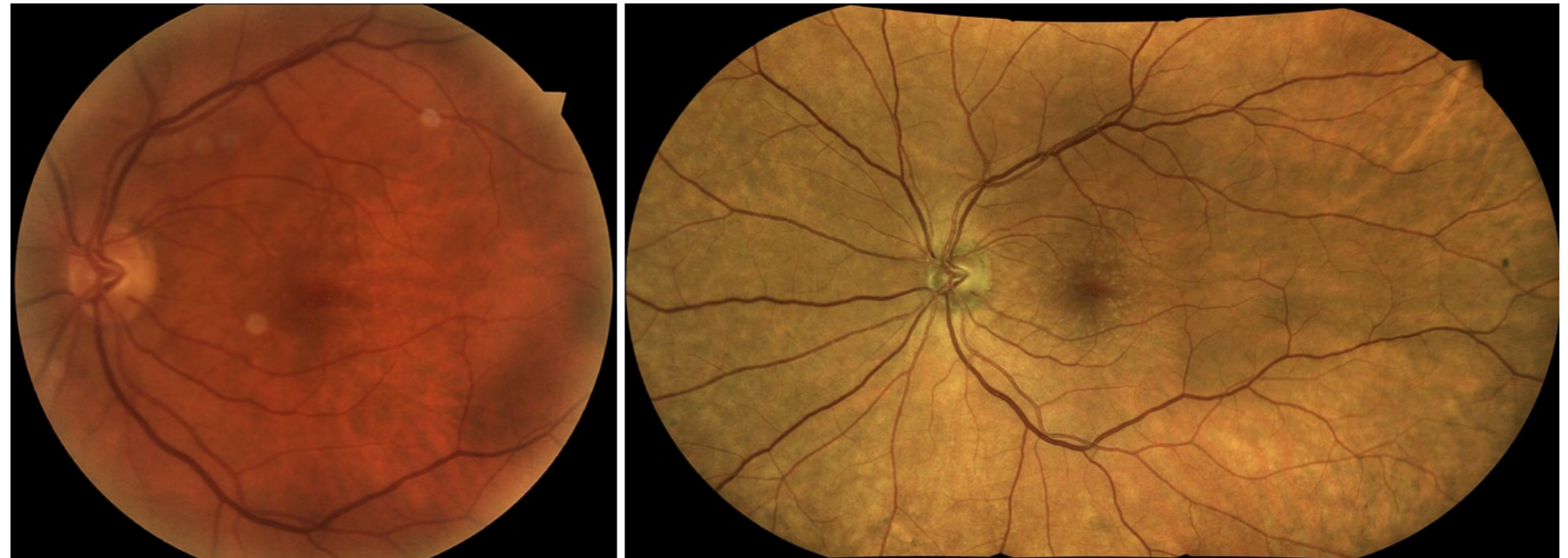
it's sometimes enough to have them become more compliant in managing their systemic disease.

Similarly, EIDON image resolution is good enough

to allow us to view arterial narrowing, crossing changes and small branch vein occlusions indicative of hypertensive retinopathy.

In another, less common scenario, we've been able to image Roth spots that can be indicative of leukemia or other forms of cancer. In one case, we imaged Roth spots in a child; luckily it turned out to be a virus instead of cancer but the images were enough

CLICK EACH IMAGE TO ENLARGE



Subtle Drusen with a standard fundus camera and EIDON wide field mosaic

to get the child a same day consult with a retinal specialist and pediatrician. The attention to detail this instrument provides can help clinicians detect and document diabetic vascular changes, hypertensive retinopathy, and vascular signs of serious systemic disease. We are able to use those images to educate the patient about the need to better manage their condition, or to better explain why we are requesting a specialist consult.



# 4

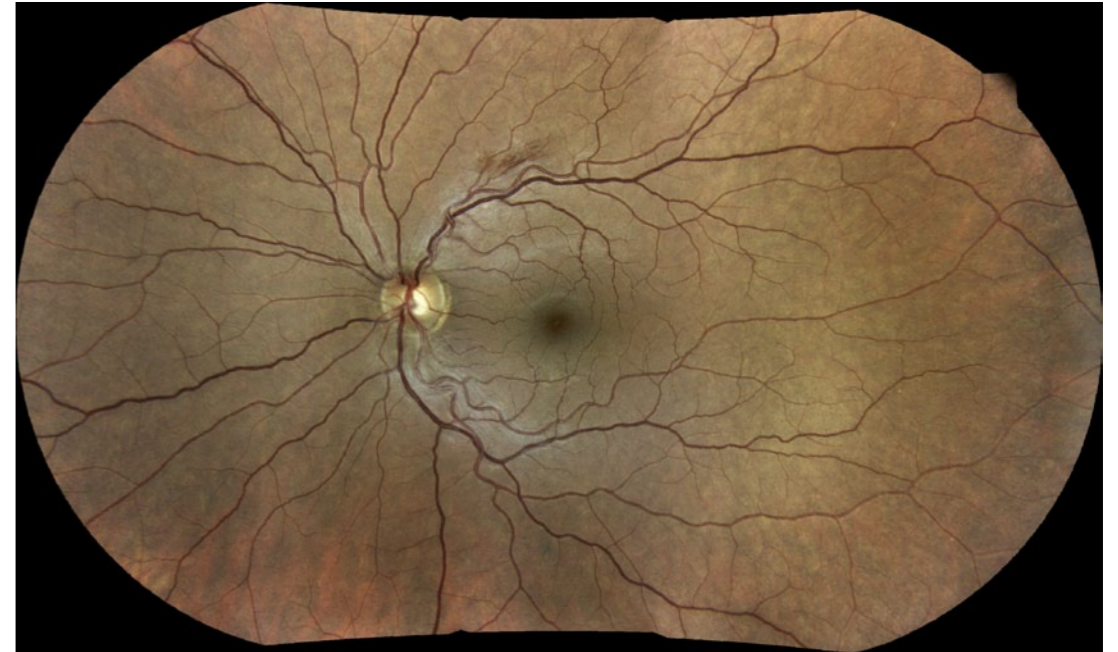## Wide-Field view

In our practice, we see on average 5 patients with diabetes daily. Typically, we'll have our techs take a wide-field image for every diabetic patient we see. Getting these wide field images is so fast it does not disrupt our patient flow. The technology really is that simple to use. It's been much, much easier to train our techs with the EIDON than it ever was on a fundus camera, and the wide-field view, approximately 110°, provides a larger retinal landscape than a fundus camera.

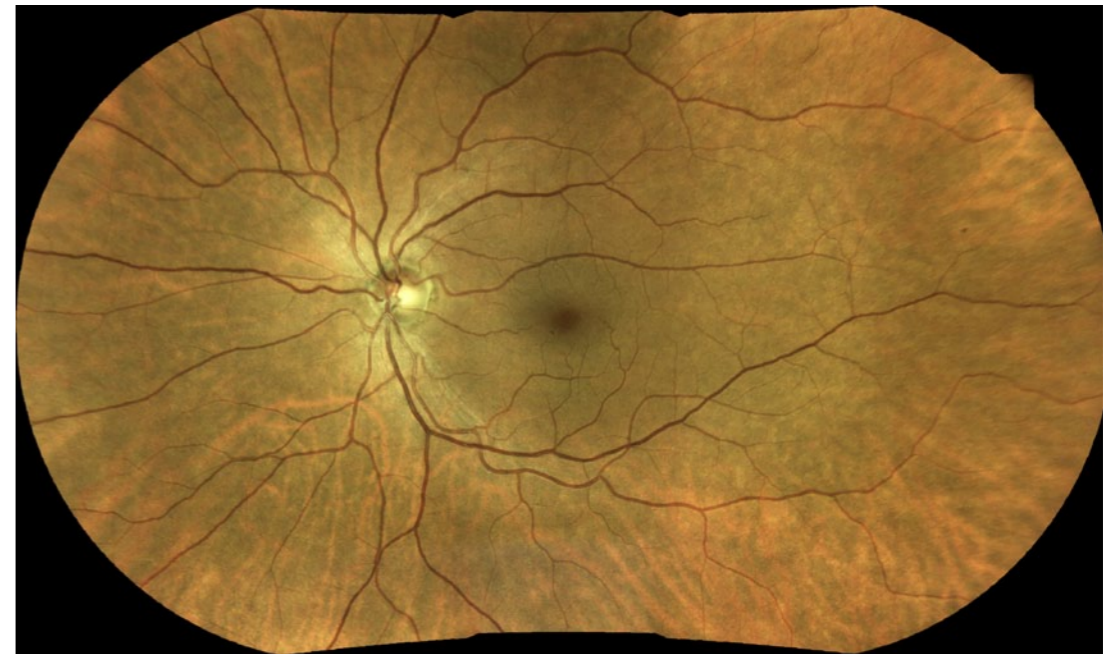EIDON allows for a wide-field image on most patients without dilation. Dilation can be an issue for a younger patient—one who needs to return to work that day, for instance—and we can image through a pupil that's as small as 2.5mm. Most young people will dilate on their own to about 3mm–4mm in a darkened room. The EIDON captures the image, locking in a clear view before the pupil can respond and contract. Being able to provide a more thorough exam for those who decline dilation is a significant advantage in a general practice.



CLICK EACH IMAGE TO ENLARGE



EIDON mosaic of Branch Retinal Vein Occlusion



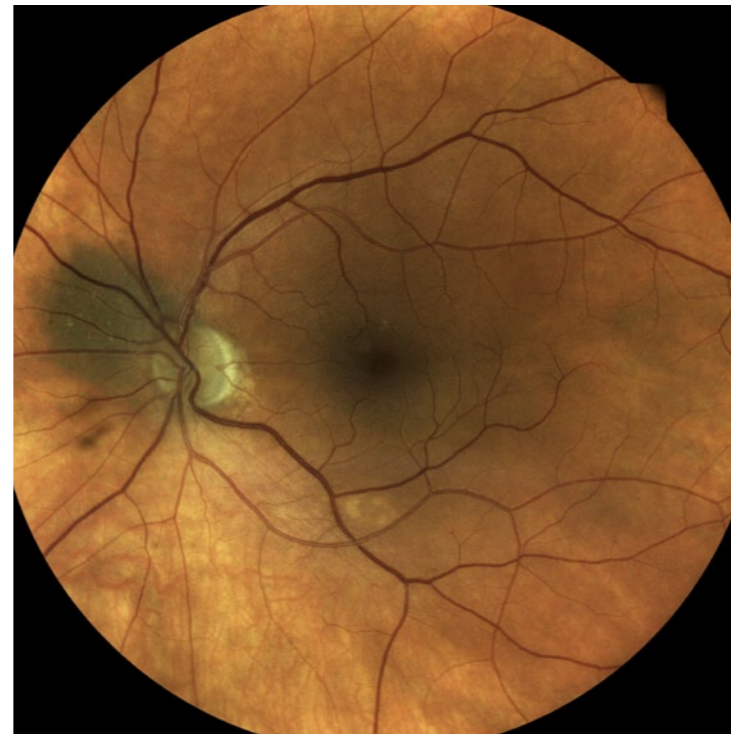EIDON mosaic of Dot Hemorrhages in Background Diabetic Retinopathy

# 5

## Compelling patient education: The Picture that's Worth a Thousand Words

Patients presume they are going to get a thorough exam when they first present to our offices. EIDON imaging helps us ensure that they do. When an ocular disease is detected in a comprehensive eye examination there is always some action required to preserve vision or limit the consequences of the disease state, yet patients are notorious for non-compliance with healthcare recommendations. This makes more effective communication using EIDON images a critical component in getting patients to cooperate with the needed care plan.

CLICK IMAGE TO ENLARGE



EIDON 60° Nevus

When shown the images of their eye, patients are amazed by the quality. It makes those miniscule vessels come alive, as though they're in 3D. So, for instance, you can tell a patient with one optic nerve significantly larger than another that they need to return for a series of tests to evaluate for glaucoma, but because patients are unlikely to know what an optic nerve is or why it's important, they may cancel appointments for subsequent testing. But with high-resolution imaging you can place the two retinal images side-by-side in the exam room and point out the size differences between the nerves. This can help to better explain why you're concerned, and increase compliance with the required testing.

5

*Continued*

You can discuss an especially large nevus in a patient’s eye and that you want to monitor the progression every 6 months—but expect to see a confused look on the patient’s face. Or, you can display the nevus in high definition on a large monitor and the need for follow-up is then clear.

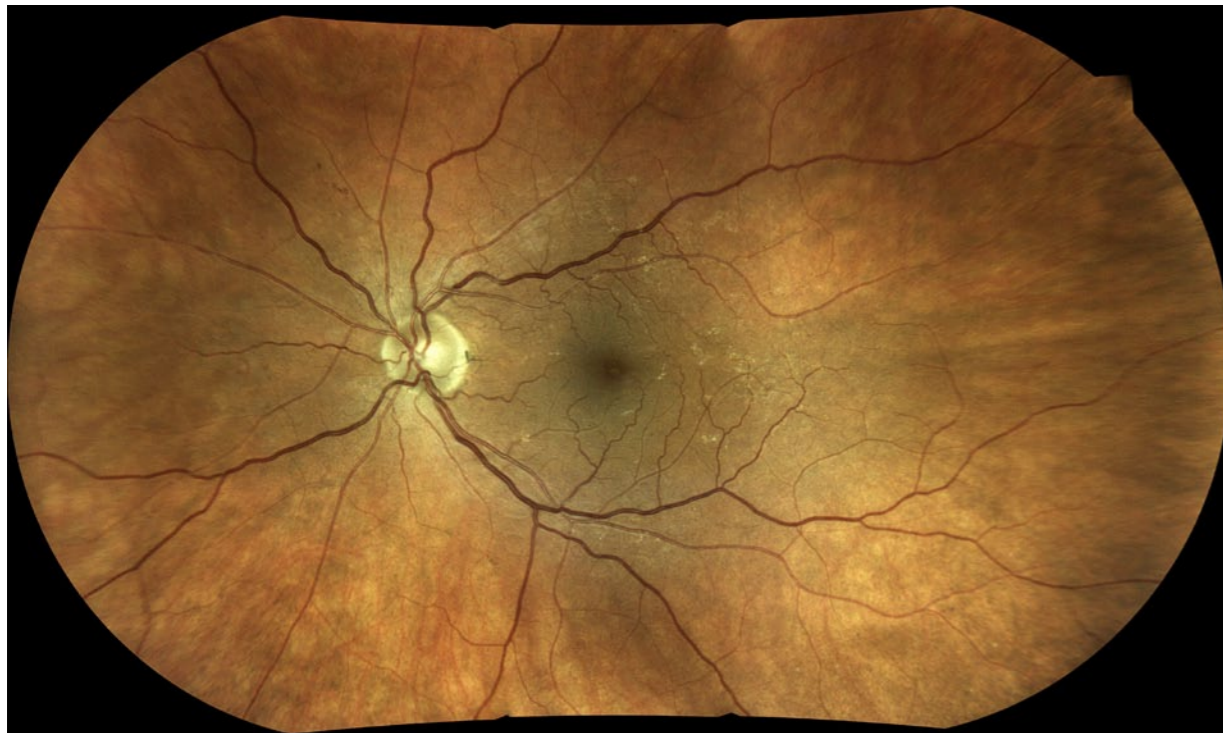
You can tell someone who smokes and has macular drusen that smoking will lead to age-related macular

degeneration and blindness, or you can show them the damage that has already been done with images from EIDON. Their willingness to consider smoking cessation assistance is more likely to improve.

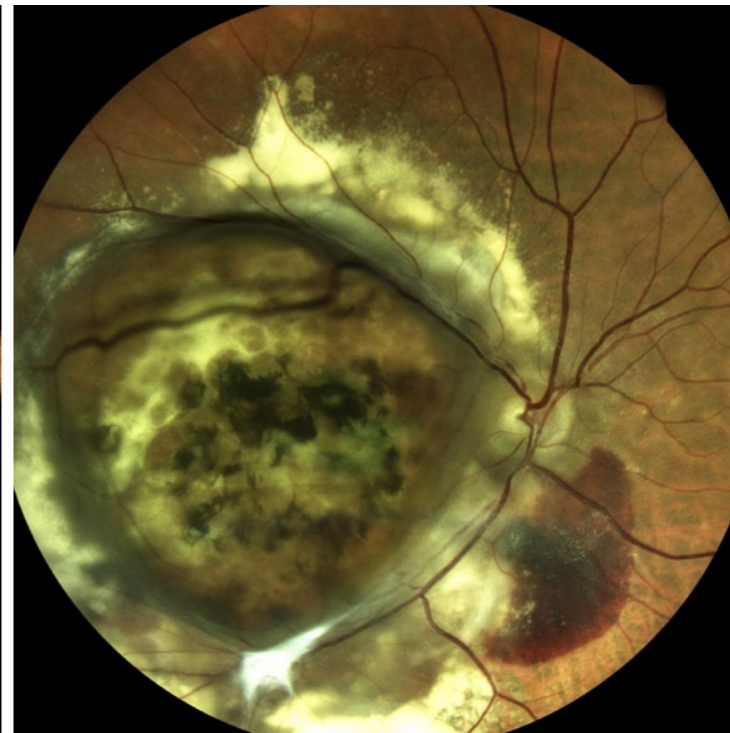
Even in normal screenings, EIDON images act as a baseline to monitor future disease progression and cements the idea in our patients’ minds that our office is “high tech.” We’ve often heard from our

patients that their last doctor “never showed them their eye.” Once you have their baseline images, patients have more incentive to stay with you so future comparisons can be made.

CLICK EACH IMAGE TO ENLARGE



EIDON mosaic of Subtle Hemorrhages and Hypertension



EIDON 60° End-Stage Exudative AMD